CLEFT RHINOPLASTY

Prof. Dr. Dr. Srinivas Gosla Reddy
MBBS, MDS, FRCS (Edin.), FDSRCS (Edin), FDSRCS (Eng.), FDSRCPS (Glasg.), Phd

Dr. Rajgopal R. Reddy
MBBS, BDS, FDSRCPS (Glasg.)

Dr. Ashish Fanan M.D.S
Dr. Avni Pandey M.D.S.

GSR Institute of Craniofacial Surgery,
Hyderabad India

Congenital Nasal Defect

Cleft Nasal Defect

Craniofacial Nasal Defect

Craniofacial Nasal Defect

Tessier # 2 facial cleft

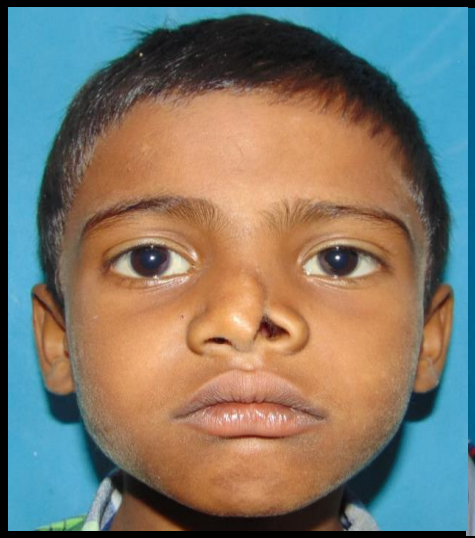

Tessier # 3 facial cleft

Cleft Nose Defect

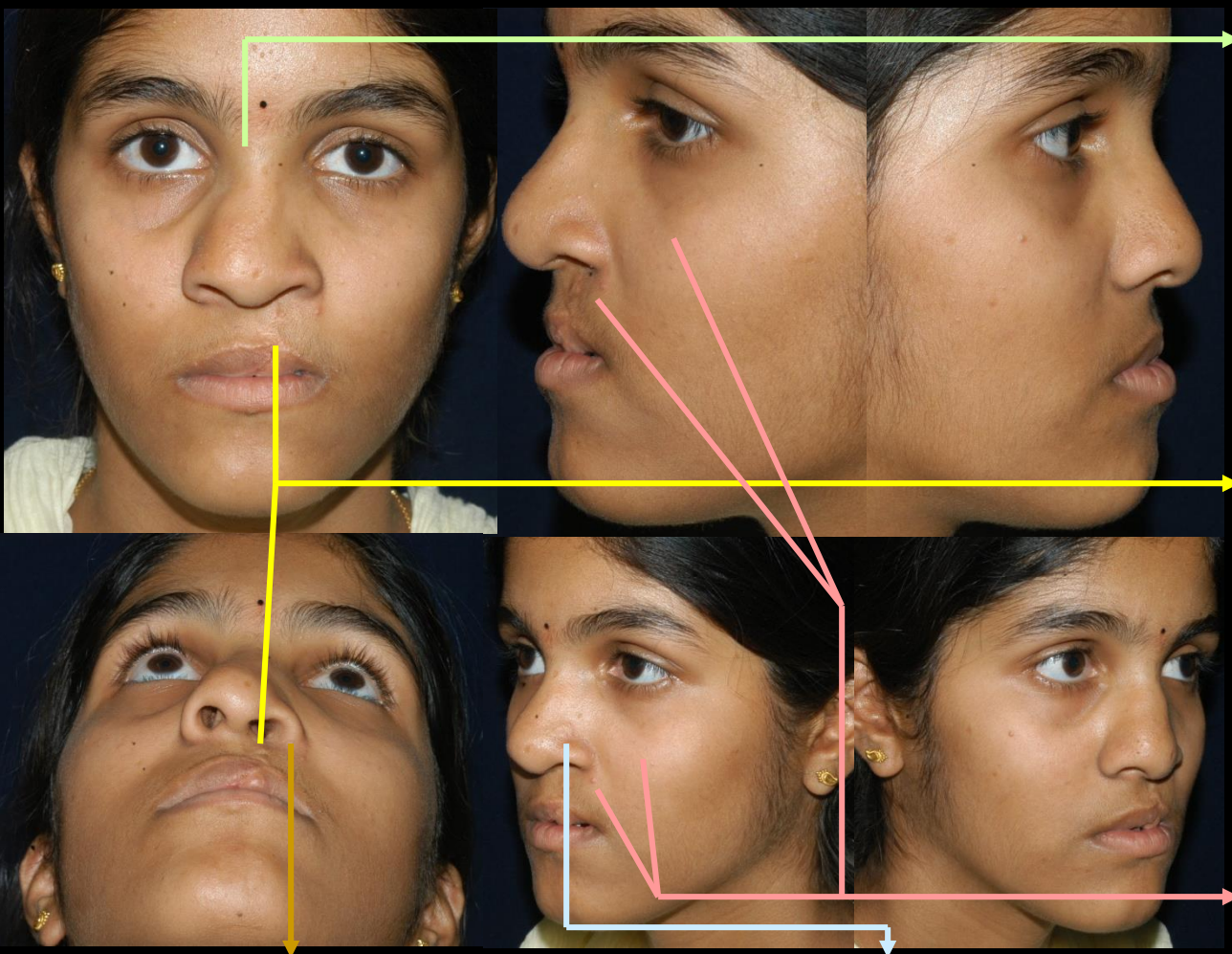

SEPTAL DEVIATION towards non cleft side due to lateral position of anterior nasal spine

SCAR of the cleft lip surgery distorting the ala

Underlying alveolar and piriform BONY DEFECT not stabilized
Maxillary Hypoplasia on cleft side

NASALIS MUSCLE not positioned during primary lip repair

OVERLYING SKIN stretched over the nostril on cleft side

Cleft Nose Defect: Problem Pentacle

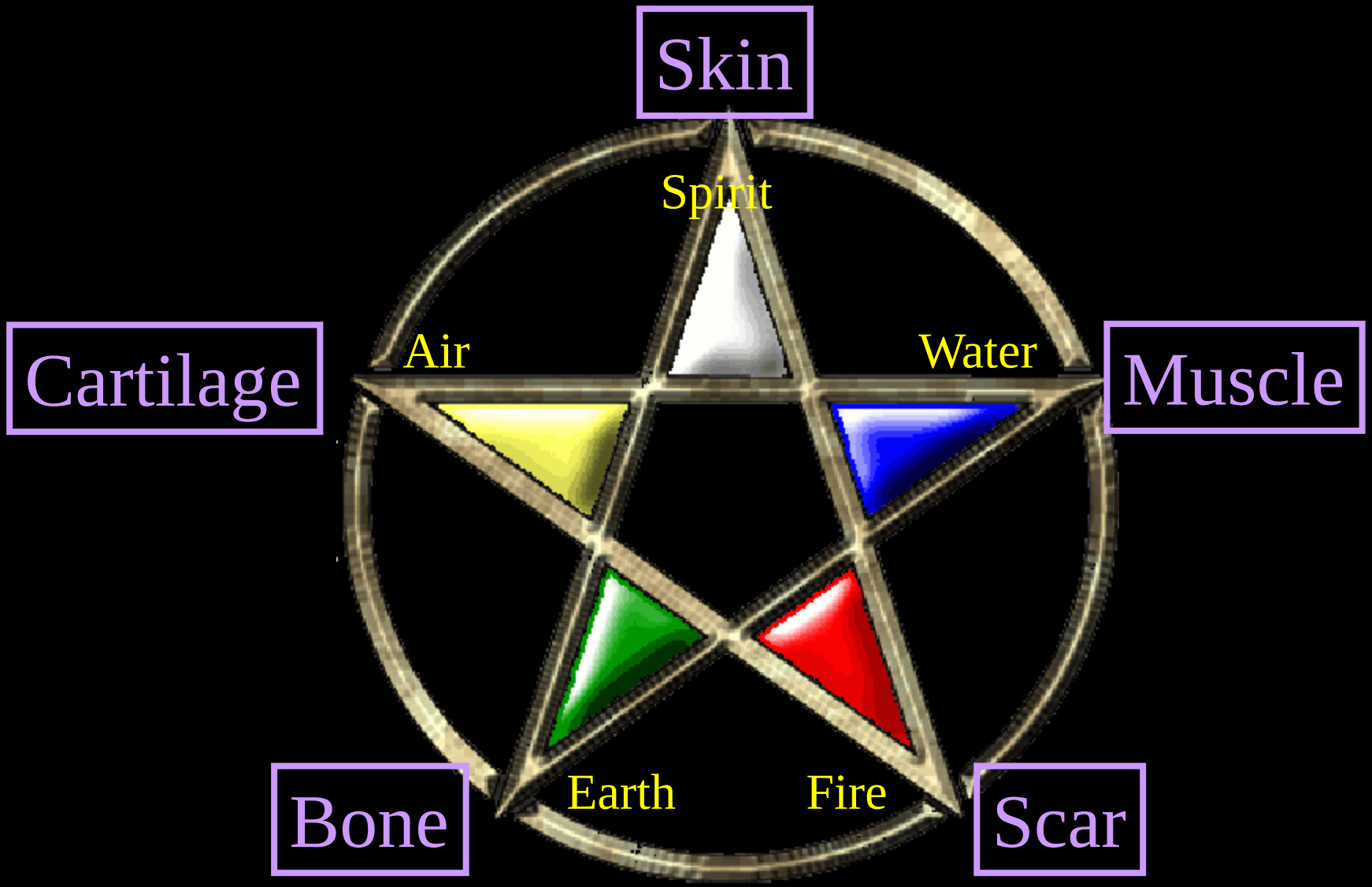

Cleft Rhinoplasty

Treatment for the cleft nose has to include all or some of the following

Rhinoplasty with

Secondary lip repair,

Alveolar bone grafting and

Maxillary advancement

We should call it PROFILOPLASTY

Anatomy of cleft nose : Unilateral Cleft

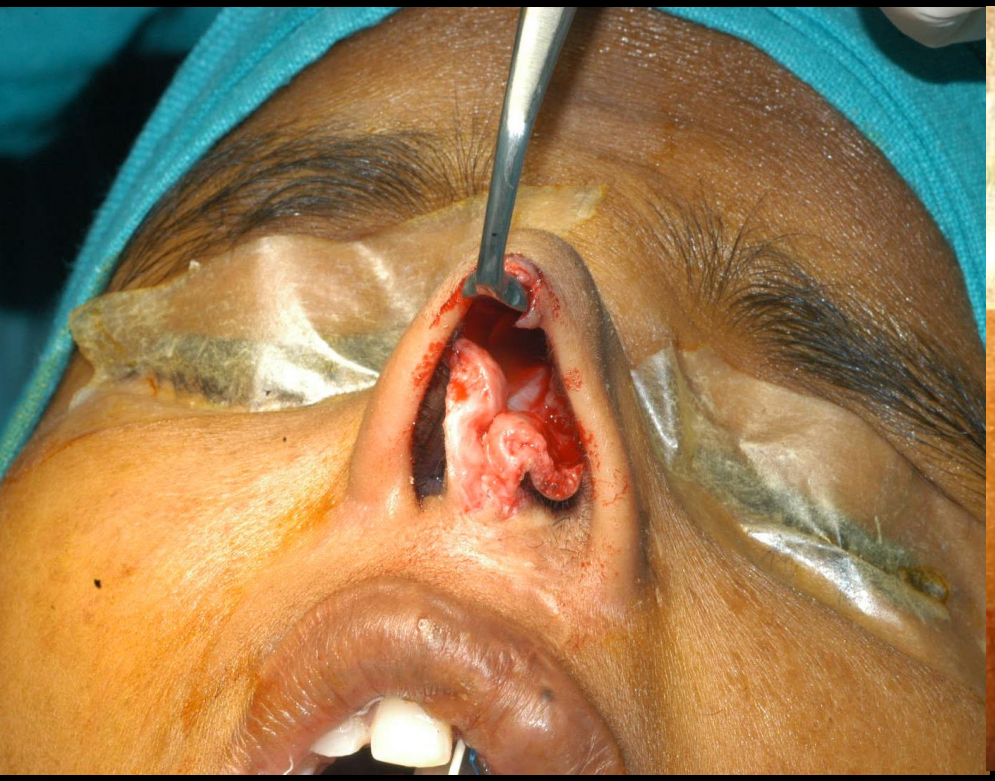

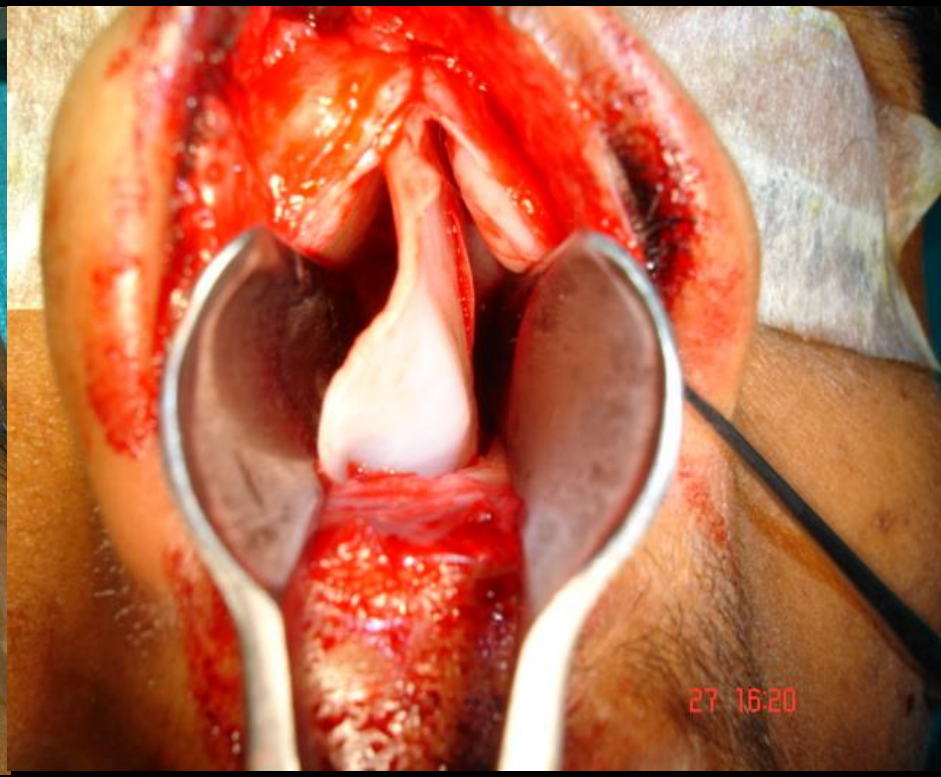

- The alar cartilages will not be at the same level
- The septum will be deviated towards the non cleft side

Anatomy of cleft nose : Bilateral Cleft

- The alar cartilages may be at the same level but will be buckled
- The septum will not be deviated but will also be buckled

Surgical Approach

Open Rhinoplasty

1. Using Septal Graft
2. Using Costo-chondral or alloplastic implants

The Need for Maxillary Advancement

Prior to Rhinoplasty

The Need for Bone Grafting

Prior to Rhinoplasty

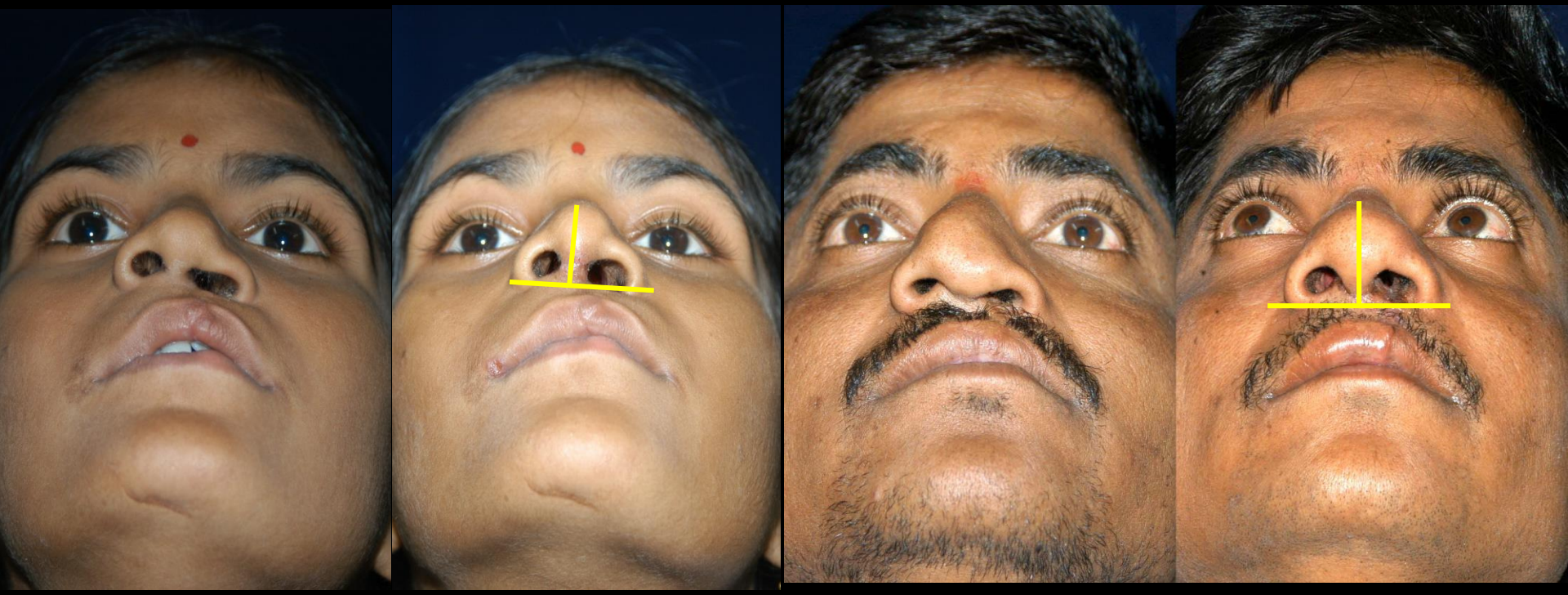

Surgical approach:

Unilateral Cleft with Septal Grafting

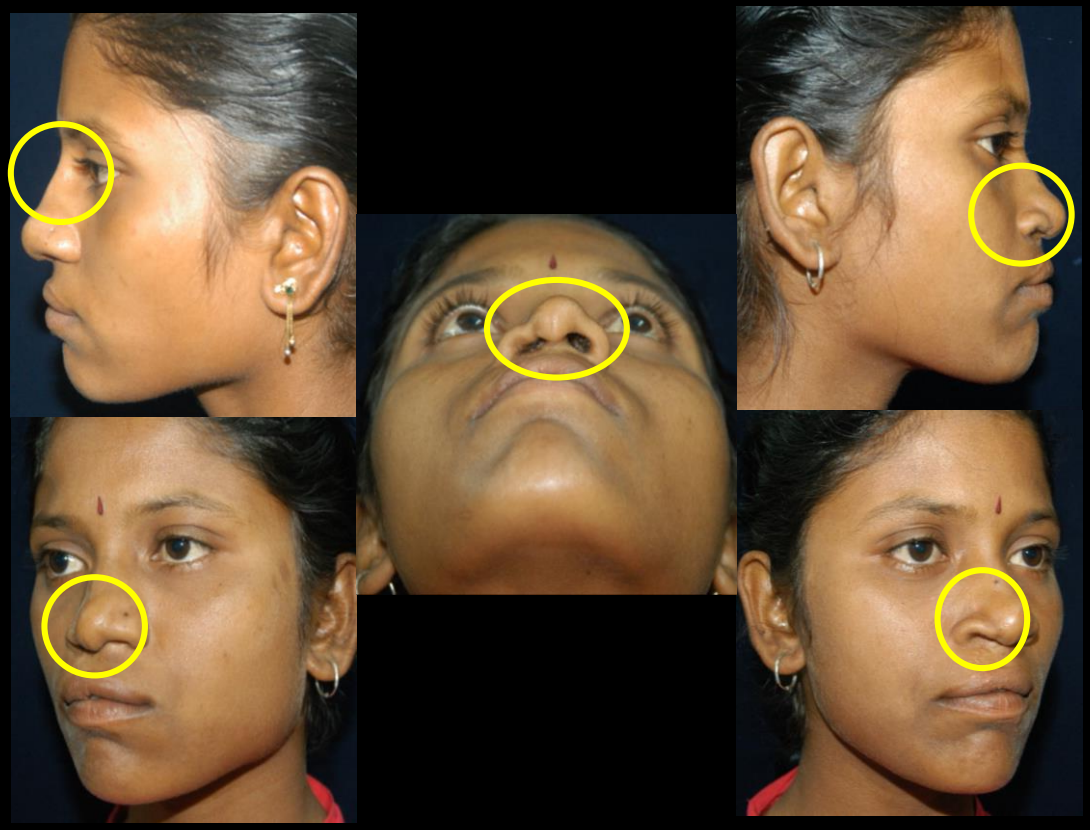

-Columella Lengthening,

- Septal Repositioning,

- Radix Grafting,

- Tip Augmentation,

- Lower Lateral Cartilage Repositioning,

-Alar Base Wedge Resections,

- Piriform Augmentation,

-Nasal Bone Osteotomies

S. Gosla Reddy et al. / Assessment of nostril symmetry after primary cleft rhinoplasty in patients with complete unilateral cleft lip and palate; Journal of Cranio-Maxillo-Facial Surgery 41 (2013) 147 -152

Cleft Rhinoplasty

Unilateral Cleft with Septal Grafting

Marking

Tejima

- Decreases the excess soft triangle tissue and reduces the nasal web.

V- Y

- Increases length of columella
- Especially increases length of medial crura
- Revise the cleft lip scar contracture.

Cleft Rhinoplasty

Unilateral Cleft with Septal Grafting

Marking

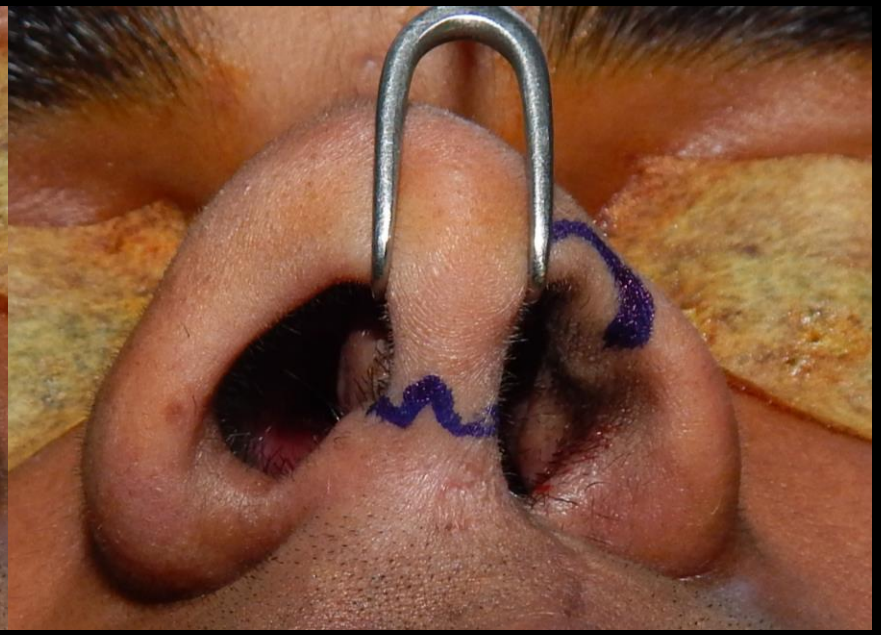

Tejima

-Decreases the excess soft triangle tissue and reduces the nasal web.

- Medial rotation of tejima flap gives columellar length on cleft side

Transcolumellar

Indicated in

- Narrowed cleft nostril
- Scar at columellar base

The rule of 5 R's for Deviated Nasal Septum

-Relieve,

-Resect,

-Reposition,

-Restructure

-Restrengthen

Cleft Rhinoplasty

Unilateral Cleft with Septal Grafting

- Relieve
- Exposing the septum
  - Note the extreme angle of caudal part of the septum due to its attachment to the anterior nasal spine which in cleft defects is lateralized towards the cleft side.

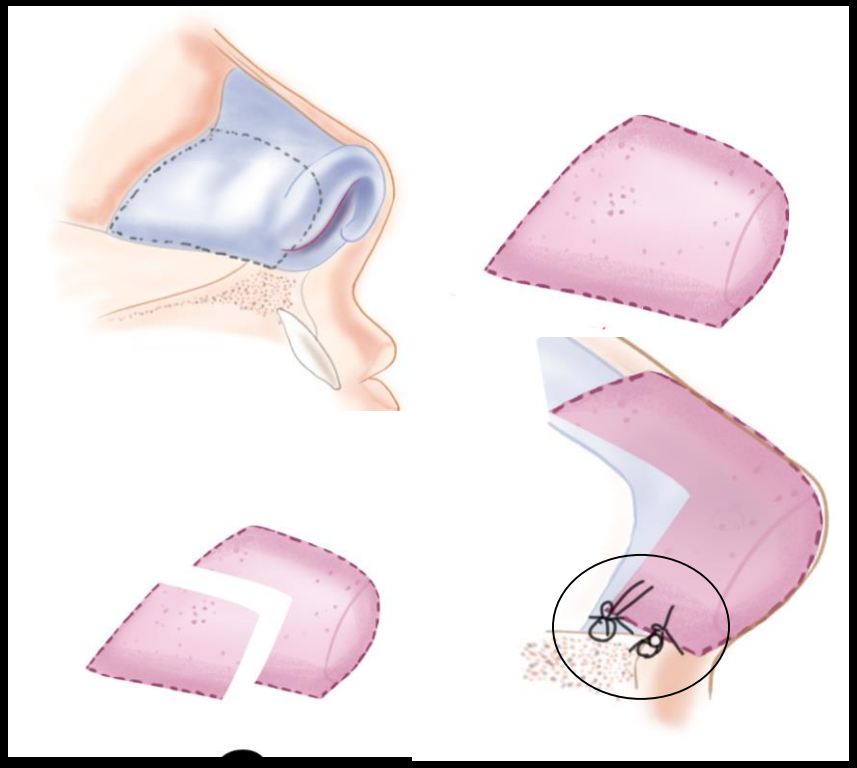

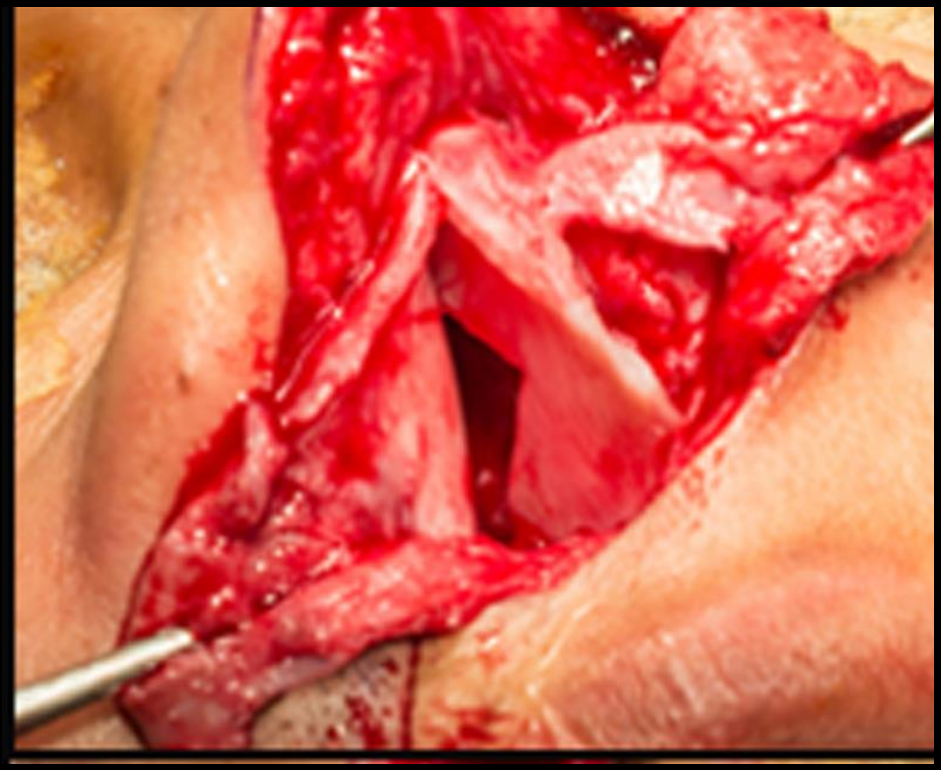

Resect

- At least 1 cm should be maintained superiorly and anteriorly in an 'L' shaped configuration to provide support for the nose.

- Septoplasty is done by resecting the posterior and inferior end of the septum.

- The extended septal graft is then stabilised anterio- caudally by drilling a hole into the bone on the cleft side.

Cleft Rhinoplasty

Unilateral Cleft with Septal Grafting

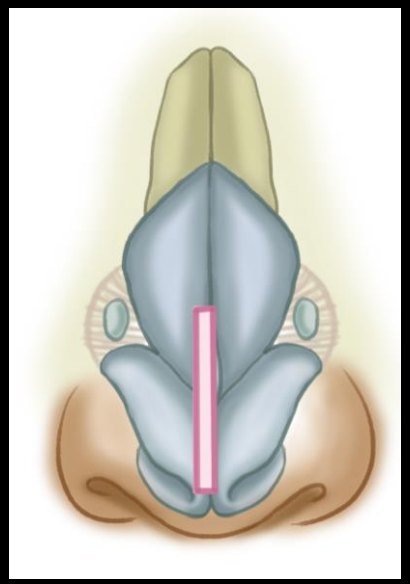

Reposition

- The septal graft extends into the medial crura and rests upon the maxillary septal groove. The septal graft also acts like a spreader graft as it is placed on the cleft side in between the upper lateral and septal cartilage .

- Closing upper lateral cartilage
  - The upper lateral cartilage needs to be opened when there is gross deviation of septum to release the bend in the septum.



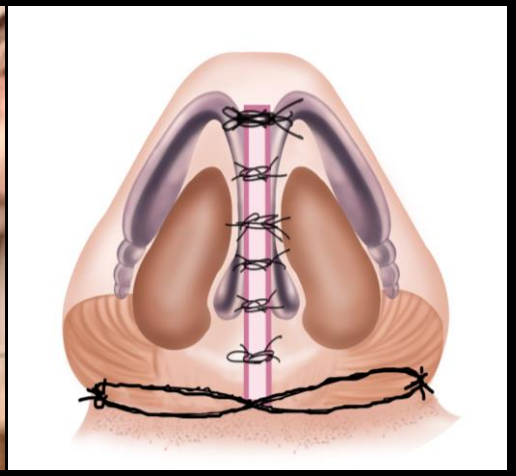

•Restructure & Restrengthen

•An 18-gauge needle is inserted through the skin at the level of alar base groove and exits at the anterocaudal part of extended septal graft.

•The antero-caudal part of septal graft is fixed in position by two bilateral alar nasalis muscle sling sutures using 4-0 polypropylene sutures.

•Medial crural footplates are sutured with septal cartilage using horizontal mattress sutures.

Closure

Quilting sutures are placed using 3-0 vicryl sutures over the nasal septum to eliminate the dead space between the dissected perichondrium on either side.

Cleft Rhinoplasty

Unilateral Cleft with Septal Grafting

Cleft Rhinoplasty

Unilateral Cleft with Septal Grafting

Cleft Rhinoplasty

Unilateral Cleft with Septal Grafting

Unilateral Cleft with Septal Grafting

Unilateral Cleft with Septal Grafting

Cleft Rhinoplasty

Bilateral Cleft with Septal Grafting

Cleft Rhinoplasty

Bilateral Cleft with Septal Grafting

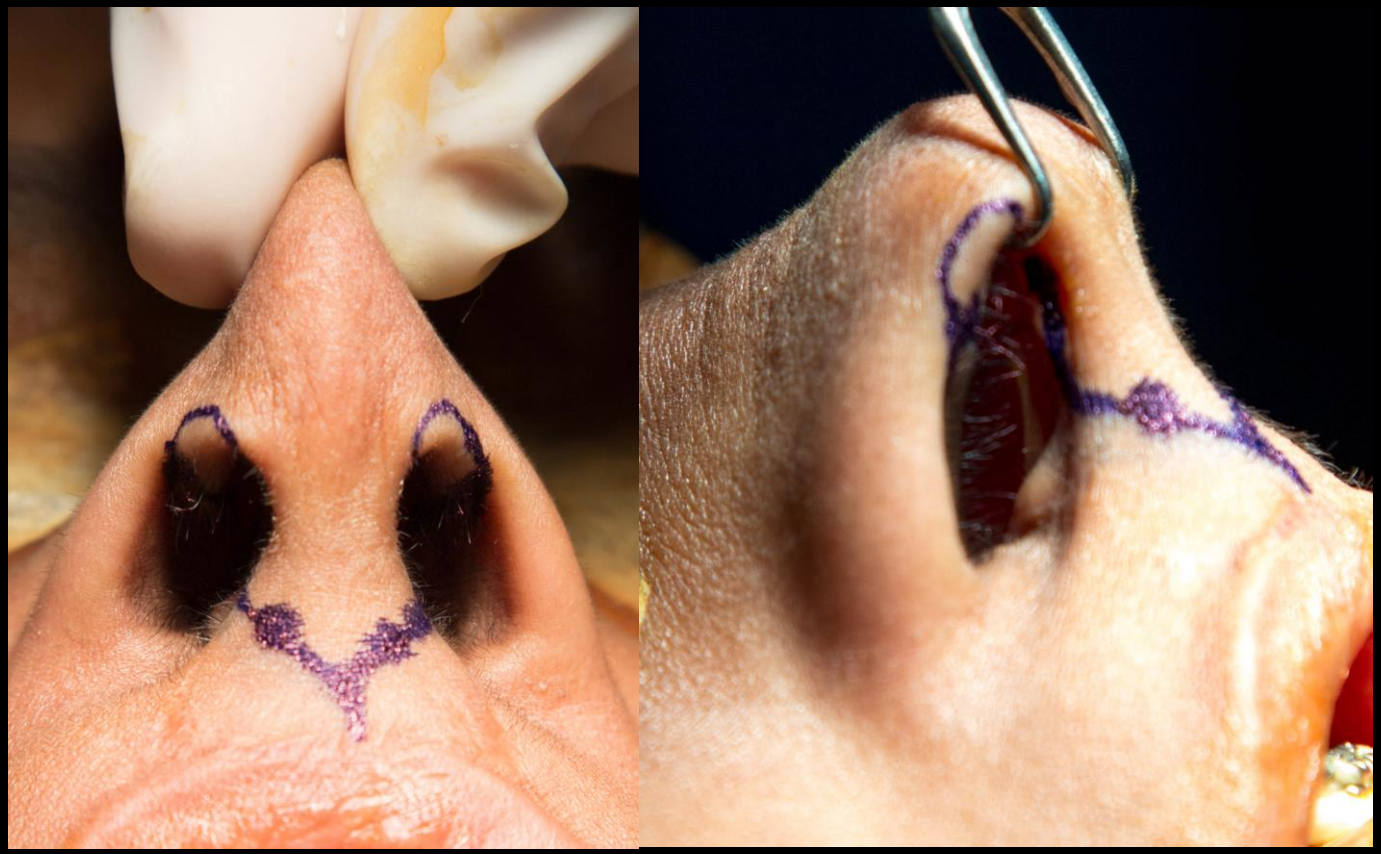

- Marking

Cleft Rhinoplasty

Bilateral Cleft with Septal Grafting

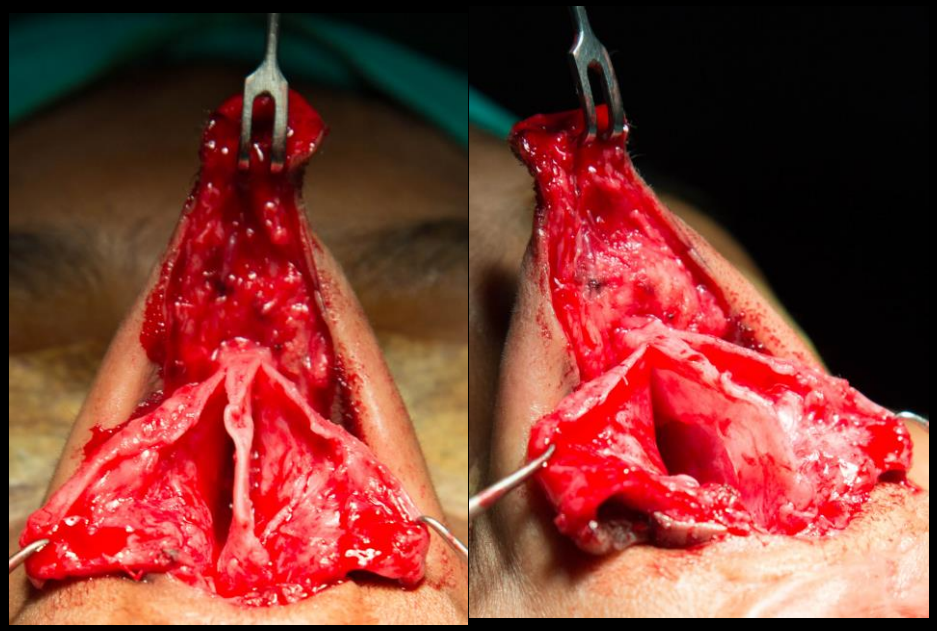

- Exposing the septum
  - Note the extreme angle of caudal part of the septum due to its attachment to the anterior nasal spine which in cleft defects is lateralized towards the cleft side
  - Septoplasty is done by resecting the posterior and inferior end of the septum

Cleft Rhinoplasty

Bilateral Cleft with Septal Grafting

- Positioning the strut made from the excised inferior and posterior part of septum
- Closing upper lateral cartilage
  - The upper lateral cartilage needs to be opened when there is gross deviation of septum to release the bend in the septum

Cleft Rhinoplasty

Bilateral Cleft with Septal Grafting

Cleft Rhinoplasty

Bilateral Cleft with Septal Grafting

Cleft Rhinoplasty

Bilateral Cleft with Septal Grafting



Cleft Rhinoplasty

Bilateral Cleft with Septal Grafting

Cleft Rhinoplasty

Unilateral Cleft with Costo-Chondral Grafting

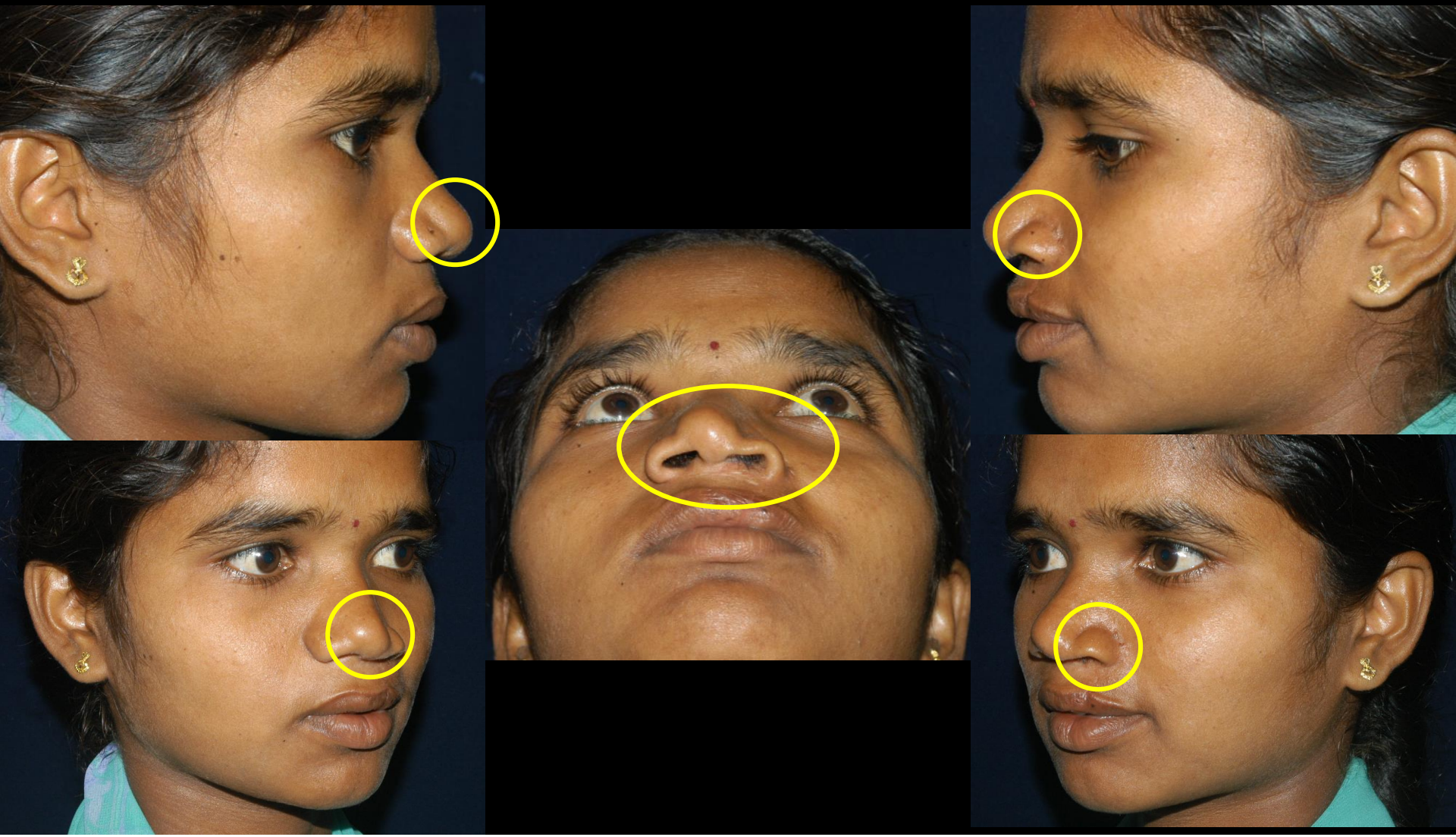

Cleft Rhinoplasty

Unilateral Cleft with Costo-Chondral Grafting

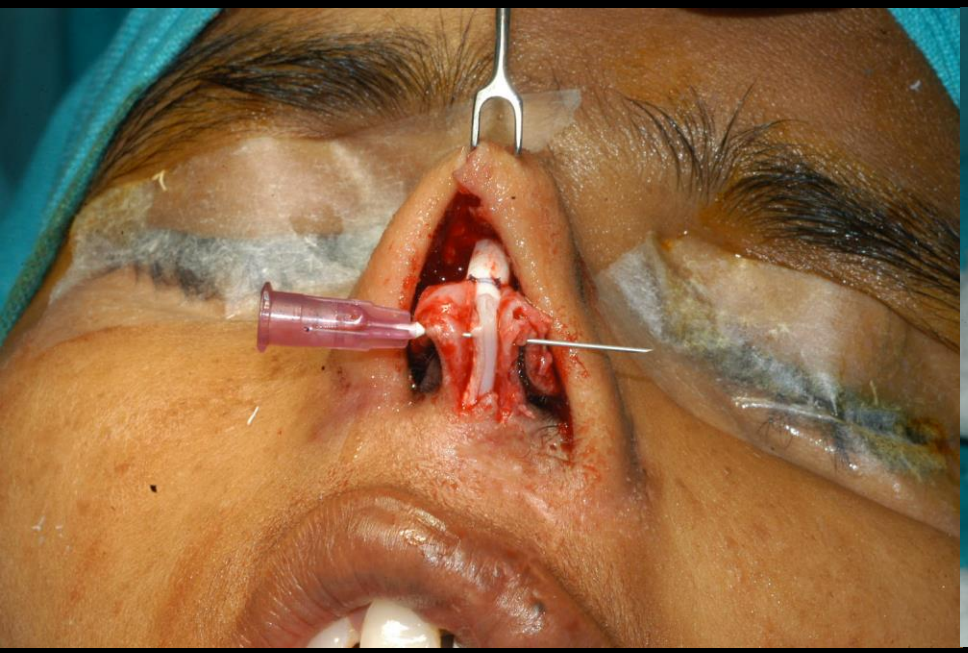

- Positioning and fixing the strut

Cleft Rhinoplasty

Unilateral Cleft with Costo-Chondral Grafting

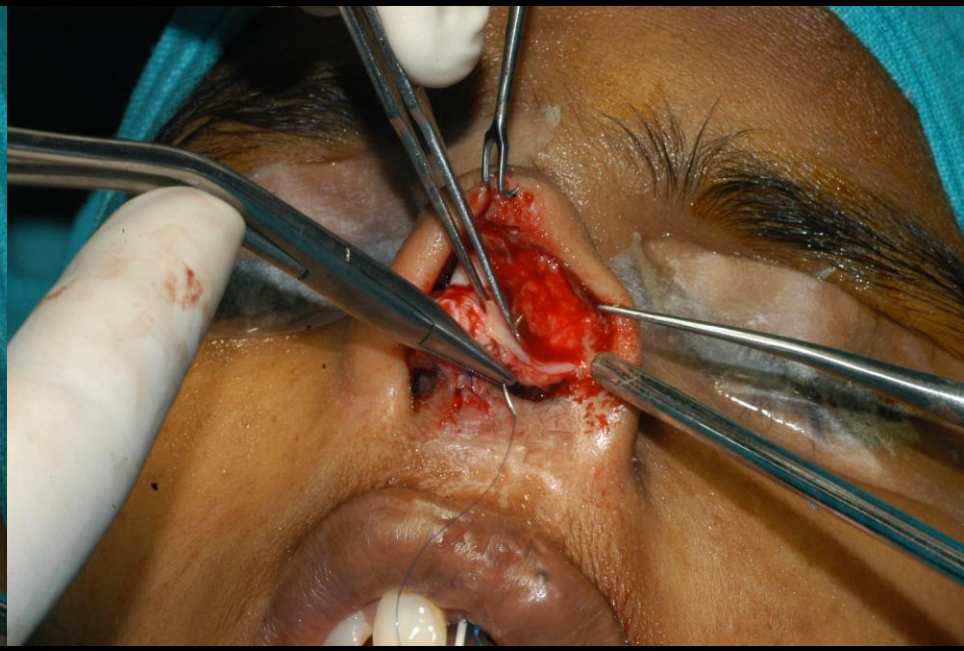

- Positioning the Baton graft to strengthen the ala on the cleft side

Cleft Rhinoplasty

Unilateral Cleft with Costo-Chondral Grafting

- Closure

Cleft Rhinoplasty

Unilateral Cleft with Costo-Chondral Grafting

Journal of Cranio-Maxillo-Facial Surgery 41 (2013) 147–152

Contents lists available at SciVerse ScienceDirect

Journal of Cranio-Maxillo-Facial Surgery

journal homepage: www.jcmfs.com

Assessment of nostril symmetry after primary cleft rhinoplasty in patients with complete unilateral cleft lip and palate☆

Srinivas Gosla Reddy*, Visalakshi Devarakonda, Rajgopal R. Reddy

GSR Institute of Craniofacial Surgery, 17-1-383/55, Vinayagar Colony, Saidabad, Hyderabad 500082, Andhra Pradesh, India

ARTICLE INFO

Article history:
Paper received 1 May 2011
Accepted 2 July 2012

Keywords:
Rhinoplasty
Dorsal onlay
Strut graft
Nostril symmetry

ABSTRACT

The aim of this study was to assess the nostril symmetry following primary cleft rhinoplasty done with either a dorsal onlay or columellar strut graft in patients with non-syndromic complete unilateral cleft lip and palate. In this retrospective study 30 consecutive patients treated with autogenous or alloplastic dorsal onlay grafts and 30 consecutive patients treated with autogenous or alloplastic columellar strut grafts for complete unilateral cleft nose reconstruction were analyzed for nasal symmetry. The autogenous grafts used were costo-chondral or septal cartilage and the alloplastic graft used was high density polyethylene (Medpore®). Assessment of the nostril symmetry was done using a two-dimensional nasal analysis 24–30 months postoperatively. Ratios between cleft and noncleft side nostril for three parameters were used to assess symmetry namely nostril width, nostril height and nostril gap area. None of the three parameters showed statistically significant changes. A satisfactory, though not statistically significant, difference in symmetrical outcome could be achieved in both the groups with the exception of nostril width symmetry in group treated with dorsal onlay graft.

1. Introduction

Despite a plethora of surgical approaches aimed at correcting the cleft nose defect, no one procedure has been universally satisfactory in the repair of nasal deformities associated with cleft lip abnormalities (Trenite et al., 1997). The various treatment options for the correction of cleft rhinoplasty include columella lengthening, septal repositioning, radix grafting, tip augmentation, tip grafting, lower lateral cartilage repositioning, alar base wedge resections, piriform augmentation and nasal bone osteotomies (Trenite et al., 1997). The typical problem with all the unilateral cleft nasal deformity which must be addressed is the nasal asymmetry. Each of the surgical techniques that have been used to correct the unilateral cleft nasal deformity has attempted to improve symmetry by translocation of the alar cartilage with its attached vestibular lining into a normal position, thereby establishing the normal vault and shape of the cartilage (Bashir et al., 2011). Several methods are reported in the literature to assess cleft lip nasal deformities, but difficulties in standardization make these studies less reproducible (Tanikawa et al., 2010).

The present study is an attempt to quantify and evaluate nostril symmetry achieved after primary rhinoplasty in patients with complete unilateral cleft lip and palate (UCLP) using a dorsal onlay and a columellar strut graft. The effect of these two techniques on the shape of the nostril was studied.

2. Materials and methods

To address the nasal deformity a retrospective study was conducted on patients operated for unilateral cleft nose deformity at our institute between January 2007 and February 2009. Thirty consecutive patients (11 males and 19 females) with dorsal grafting and 30 consecutive patients with strut grafting (11 males and 19 females) were enrolled in the study.

2.1. Surgical technique

Open structured rhinoplasty was performed by a single surgeon on all the patients. After a transcolumellar incision approach, the alar cartilages were exposed and released from their mucosal attachments. A back cut was given in the cleft side nasal vestibular mucosa to ensure a satisfactory lift of the buckled cleft side alar cartilages.

Patients with a depressed nasal bridge, drooping nasal tip and short columella of the nose were treated with a dorsal onlay graft

☆ Sources of support in the form of grants: None.
* Corresponding author. Tel.: +91 40 65764884; fax: +91 40 24530000.
E-mail address: gosla@craniofacialinstitute.org (S. Gosla Reddy).

1010-5182/$ – see front matter © 2012 European Association for Cranio-Maxillo-Facial Surgery. Published by Elsevier Ltd. All rights reserved.
http://dx.doi.org/10.1016/j.jcms.2012.07.001

S. Gosla Reddy et al.

Assessment of nostril symmetry after primary cleft rhinoplasty in patients with complete unilateral cleft lip and palate;

Journal of Cranio-Maxillo-Facial Surgery 41 (2013) 147 -152

Group 1- 30 consecutive patients with dorsal grafting

Group 2- 30 consecutive patients with strut grafting

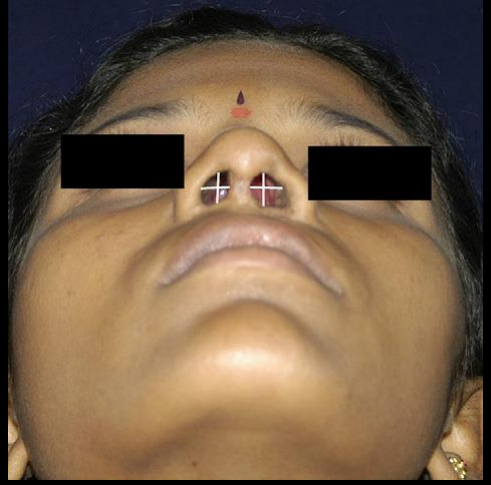

Measurement of nostril width and height

Measurement of nostril gap area

Conclusion:-

A decrease in the cleft side nostril width less than that of the noncleft side was noted after using a dorsal graft inspite of a near perfect symmetrical outcome in terms of nostril height and nostril
gap area.

Thus a satisfactory symmetrical outcome could be achieved in both the treatment groups with the exception of nostril width symmetry in group treated with dorsum graft.

There was an improvement in the nostril symmetry in patients undergoing strut grafting. This improvement, however, was not statistically significant.

3 Dimensional Photographic Analysis

3 Dimensional Photographic Equipment

3 Dimensional LASER Equipment

3 Dimensional Photographic Analysis



3D Stereophotogrammetric analysis supported by Radboud University, Nijmegen (Prof. Stefaan Berge) and University Medical Center, Basel (Prof. Hans Florian Zeilhofer)

Complex nasal deformities

Complex Nasal Deformities

Nasal Duplication

Heminasal Aplasia

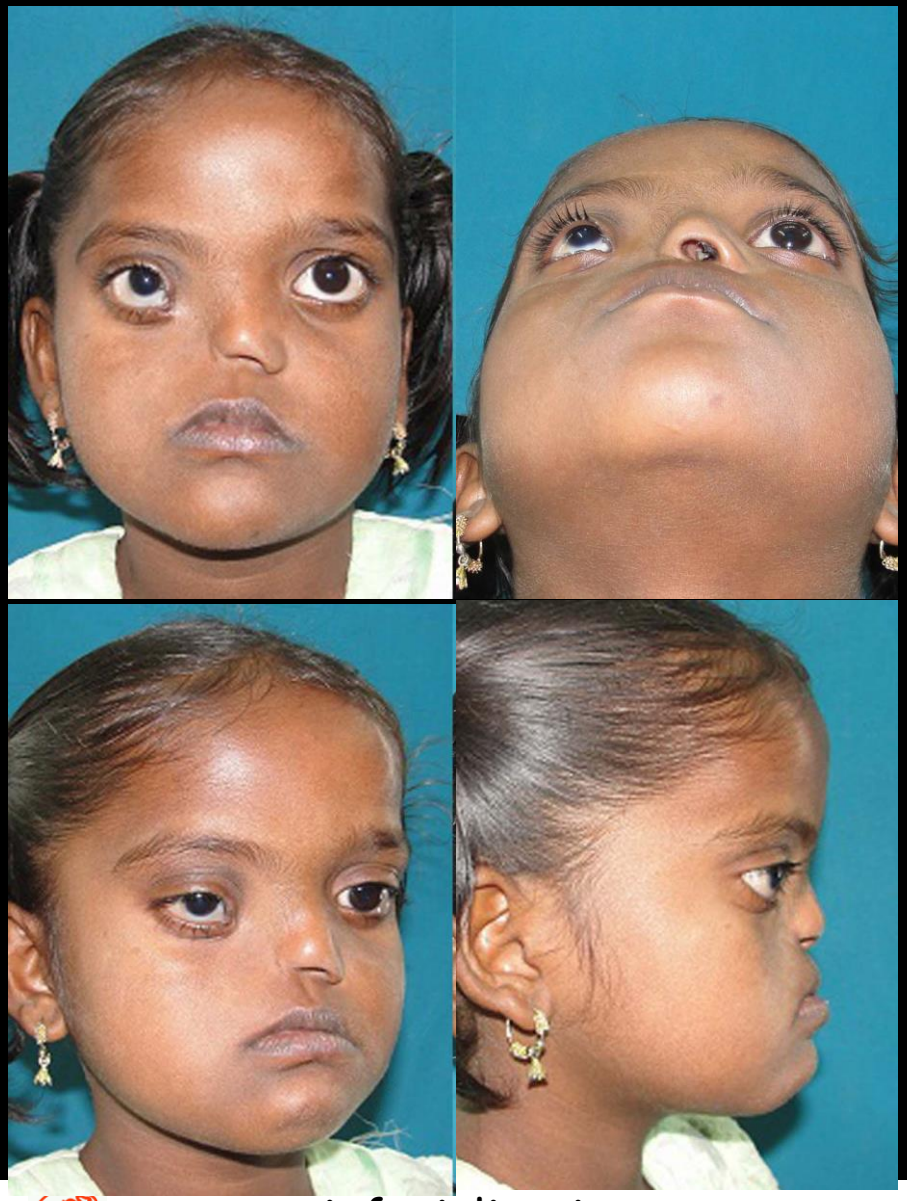

www.craniofacialinstitute.org

Heminasal Aplasia

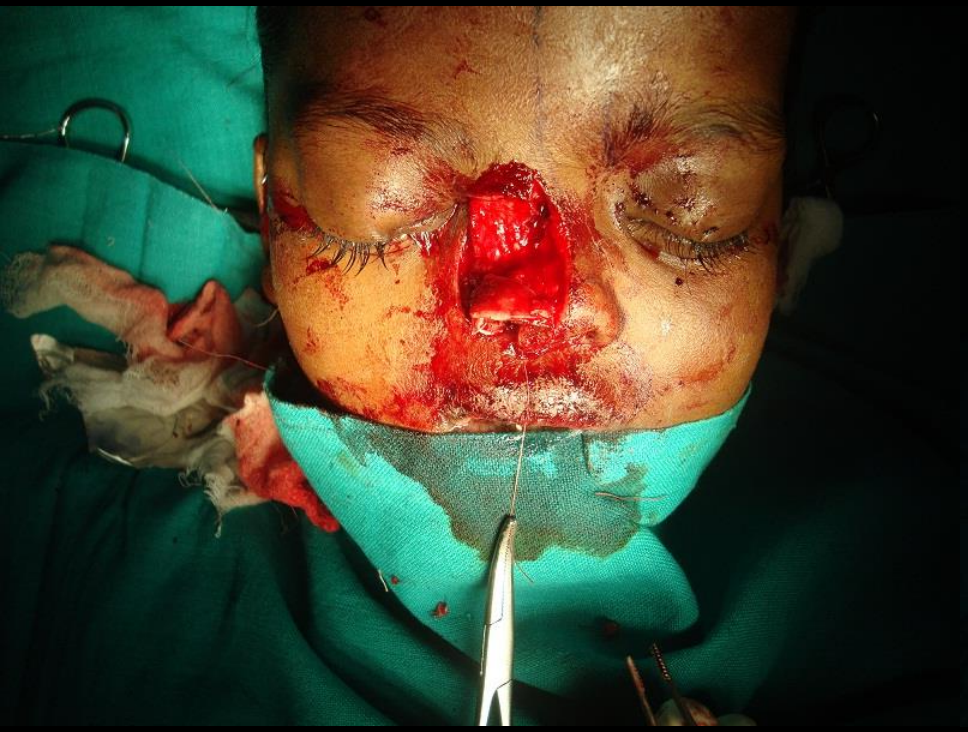

Heminasal Aplasia

www.craniofacialinstitute.org

Complex Nasal Deformities

Nasal Aplasia

Complex Nasal Deformities

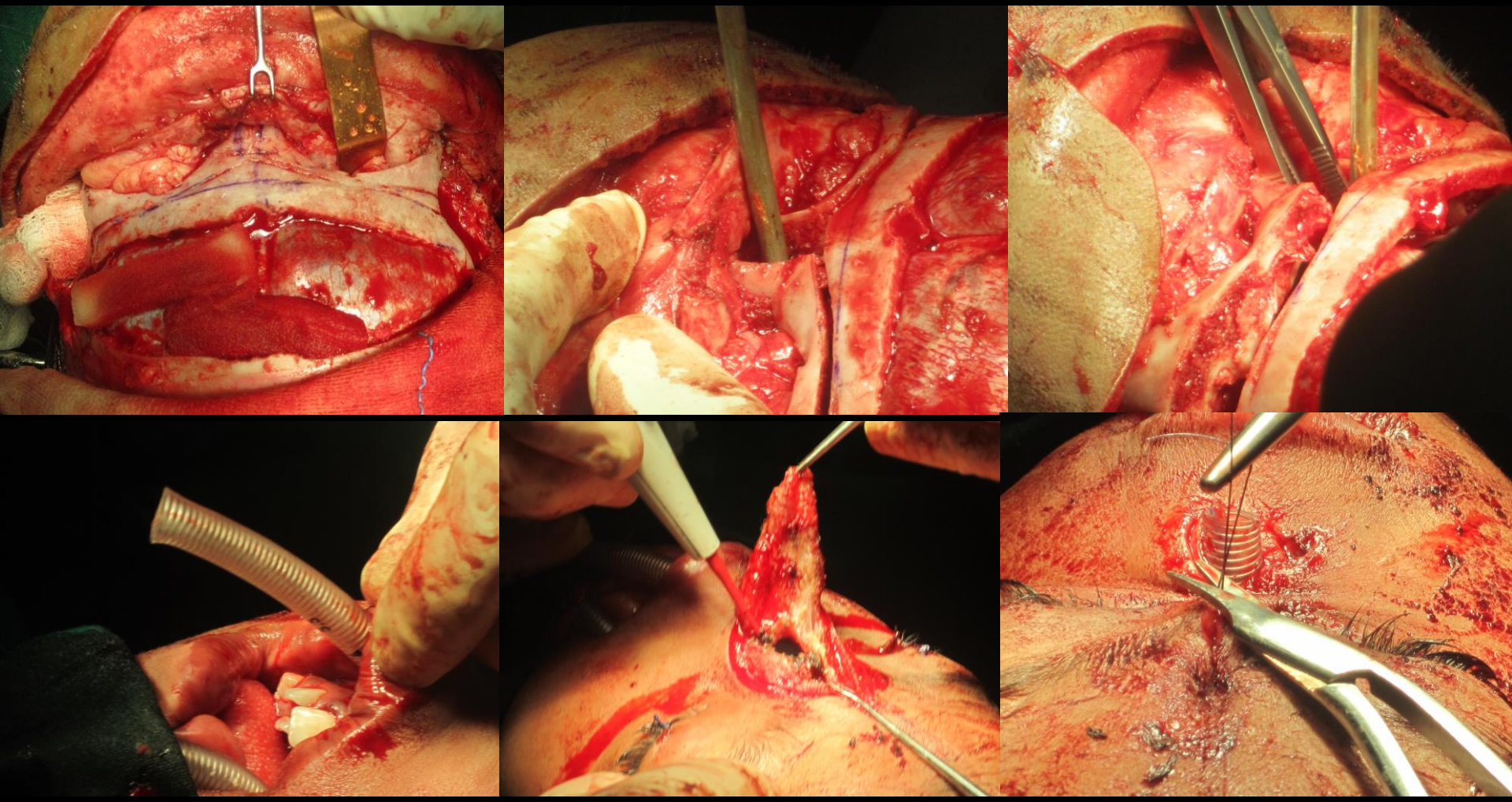

Complex Nasal Deformities

www.craniofacialinstitute.org

Complex Nasal Deformities

Tessier # 0 Facial Cleft

Complex Nasal Deformities

Tessier # 0-14 Facial Cleft

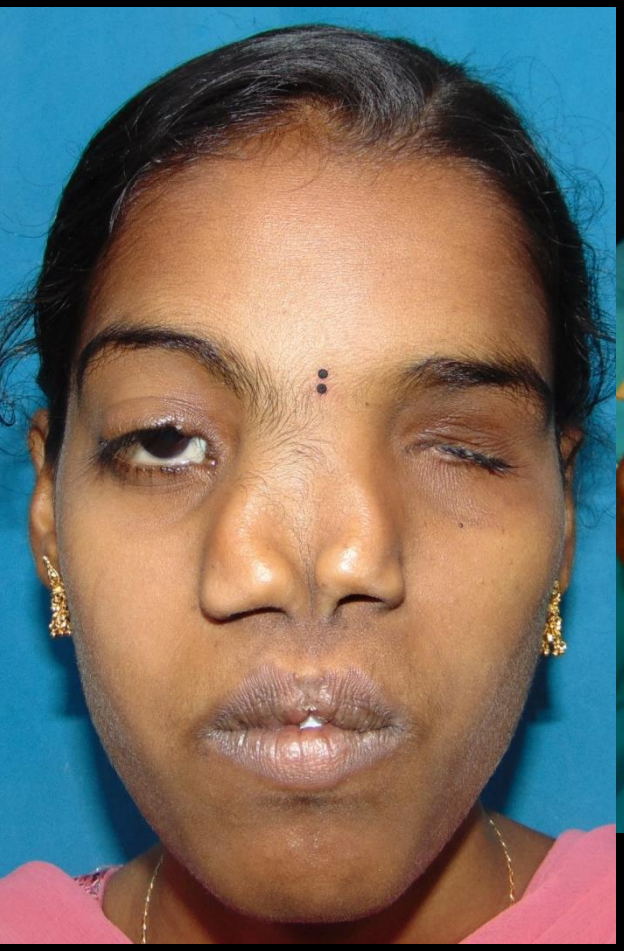

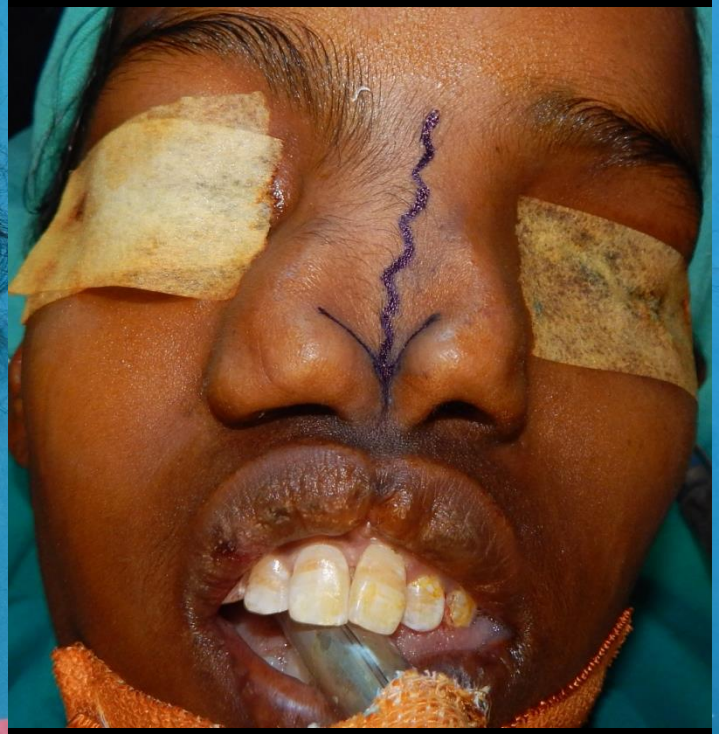

Complex Nasal Deformities

Tessier # 2 Facial Cleft

Complex Nasal Deformities

Tessier # 2 Facial Cleft

Complex Nasal Deformities

Tessier # 2 Facial Cleft

Complex Nasal Deformities

Tessier #3 Facial Cleft

Complex Nasal Deformities

Tessier #3 Facial Cleft

Complex Nasal Deformities

Tessier #3 Facial Cleft

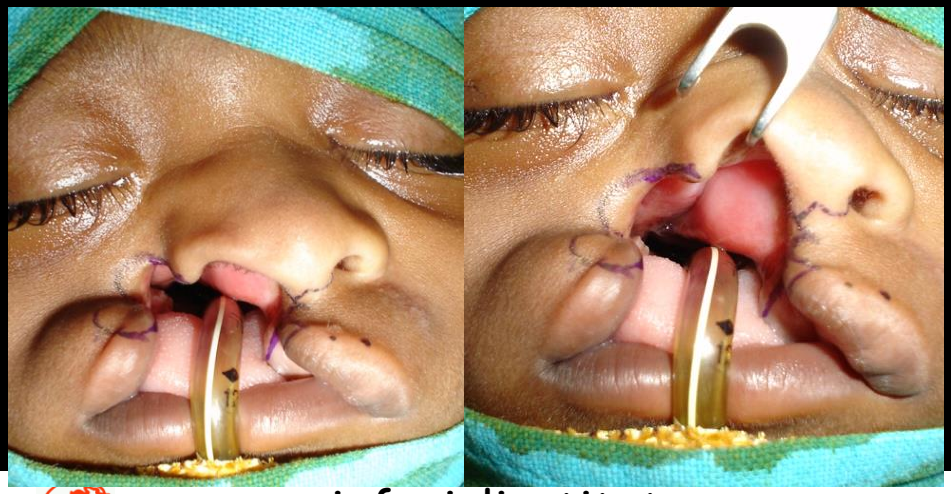

Complex Nasal Deformities

Tessier #14 Facial Cleft

Complex Nasal Deformities

Lyophilised Cartilage Graft

Complex Nasal Deformities

Bring the Smile Back