MORPHO-FUNCTIONAL REPAIR OF BILATERAL CLEFT LIP

-EVIDENCE BASED

Prof. Dr. Dr. Srinivas Gosla Reddy
MBBS, MDS, FRCS (Edin.), FDSRCS (Edin), FDSRCS (Eng.), FDSRCPS (Glasg.), PhD

Dr. Rajgopal R. Reddy
MBBS, BDS, FDSRCPS (Glasg.), PhD

Dr. Ashish Fanan M.D.S.
Dr. Avni Pandey M.D.S.

GSR Institute of Craniofacial Surgery,
Hyderabad India

Incomplete or Partial Bilateral Cleft Lip

Symmetrical cleft involving vermillion and white roll of lip without involvement of nostrils (Type I a)

Symmetrical cleft involving vermillion and white roll of lip with involvement of nostrils (Type I b)

Asymmetrical cleft involving vermillion and white roll of lip without involvement of nostrils (Type II a)

Asymmetrical cleft involving vermillion and white roll of lip with involvement of nostrils (Type II b)

Complete Bilateral Cleft Lip

Bilateral cleft lip with symmetry:
Complete cleft on both sides (Type I a)

Bilateral cleft lip without symmetry:
Complete cleft on one side and incomplete cleft on the other (Type I b)

Premaxilla within the confines of the arch
(Type II a)

Premaxilla protruding away/outside from
the arch (Type II b)

Complete Bilateral Cleft Lip

Cleft lip with prolabial-columellar angle < 120° (Type III a)

Cleft lip with prolabial-columellar angle > 120° (Type III b)

Type I b, II b, III a complete bilateral cleft lip, alveolus, hard and soft palate (Complete cleft on both sides, with premaxilla protruding away from arch and prolabial-columellar angle < 120°)

Bilateral Cleft Lip Repair

Incision design for bilateral cleft lip surgery

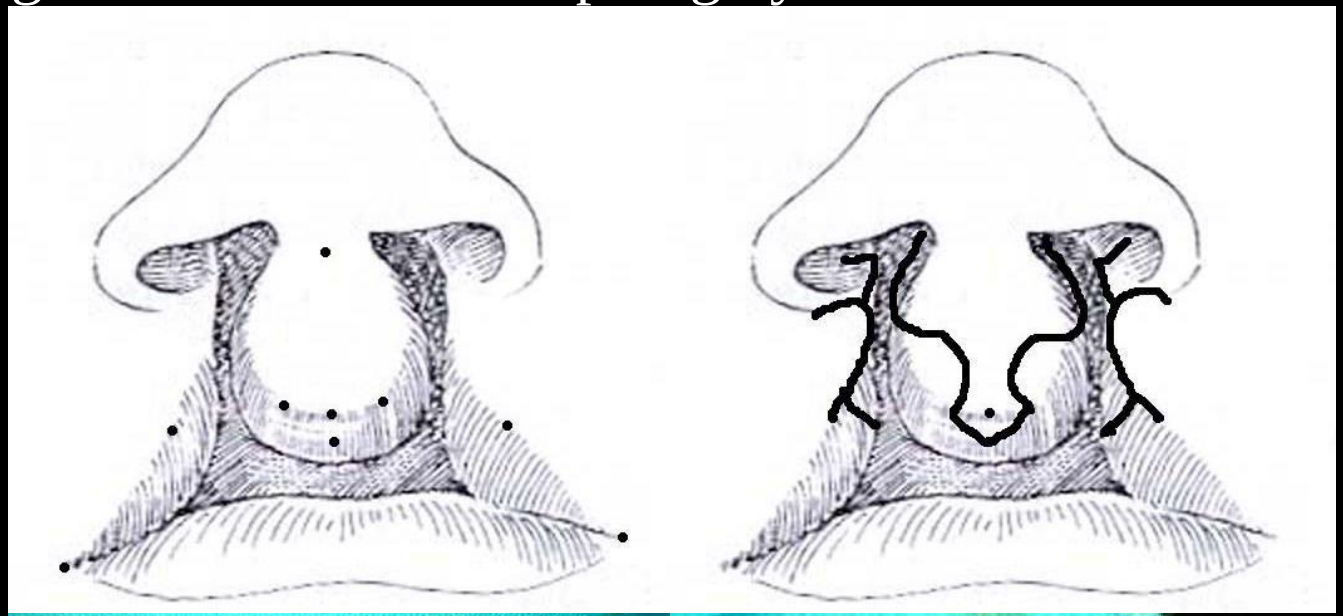

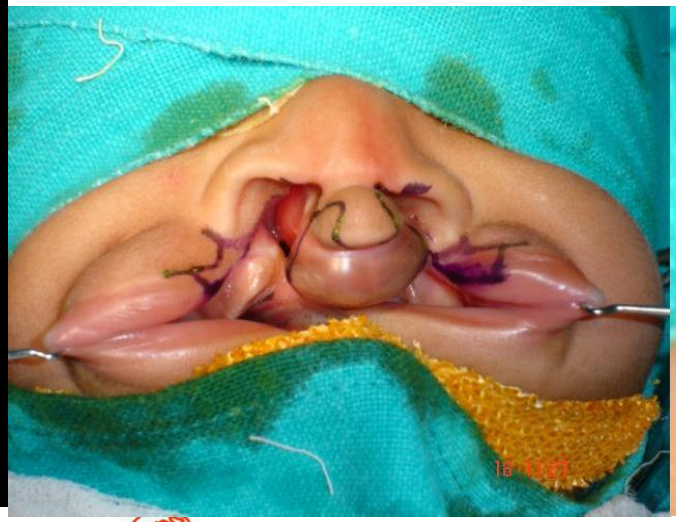

Bilateral Cleft Lip Repair

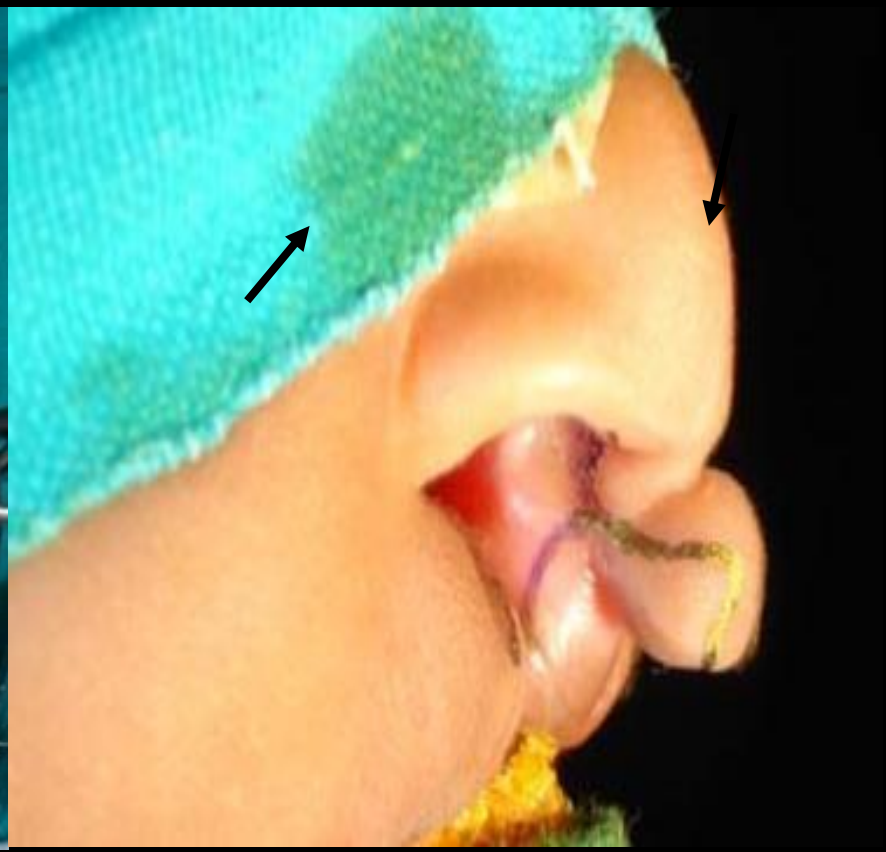

Afroze Incision

Bilateral Cleft Lip Repair

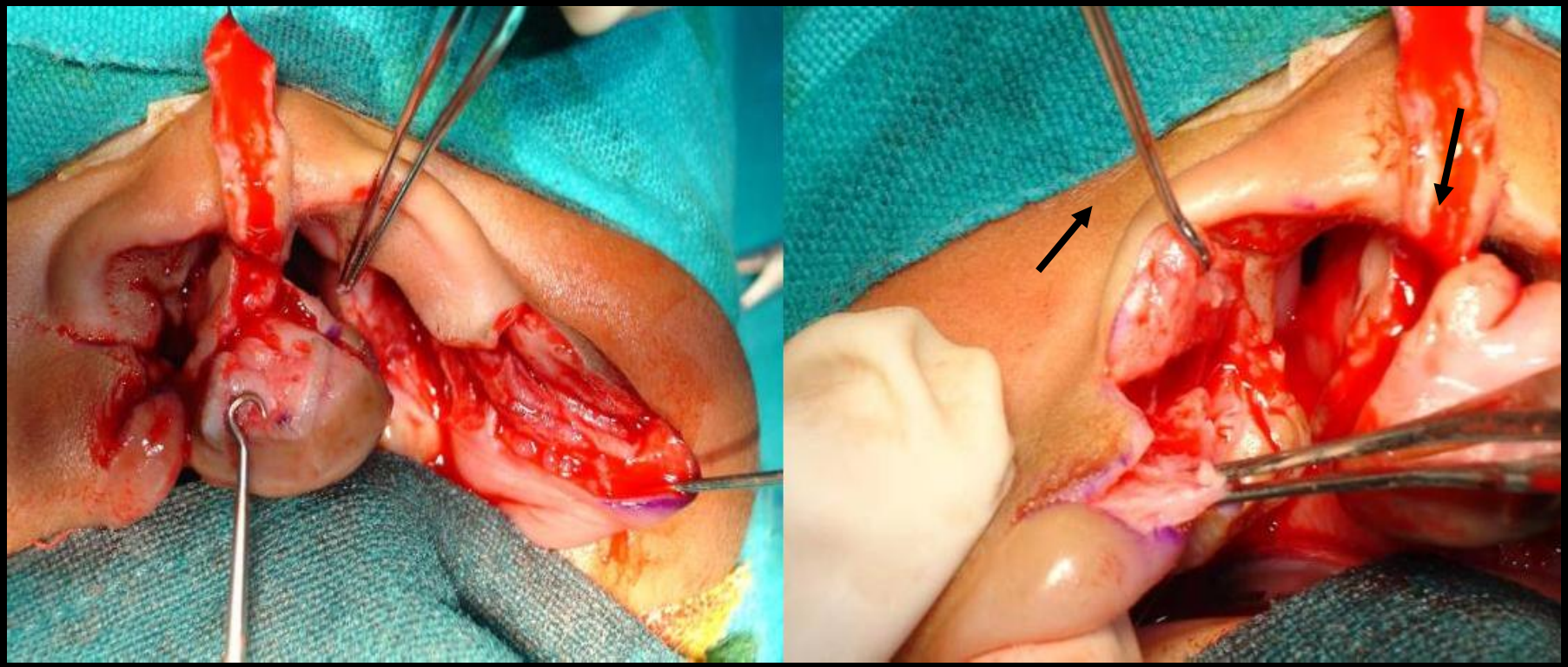

Minimal muscle dissection ensuring dissection of transverse nasalis muscle

Bilateral Cleft Lip Repair

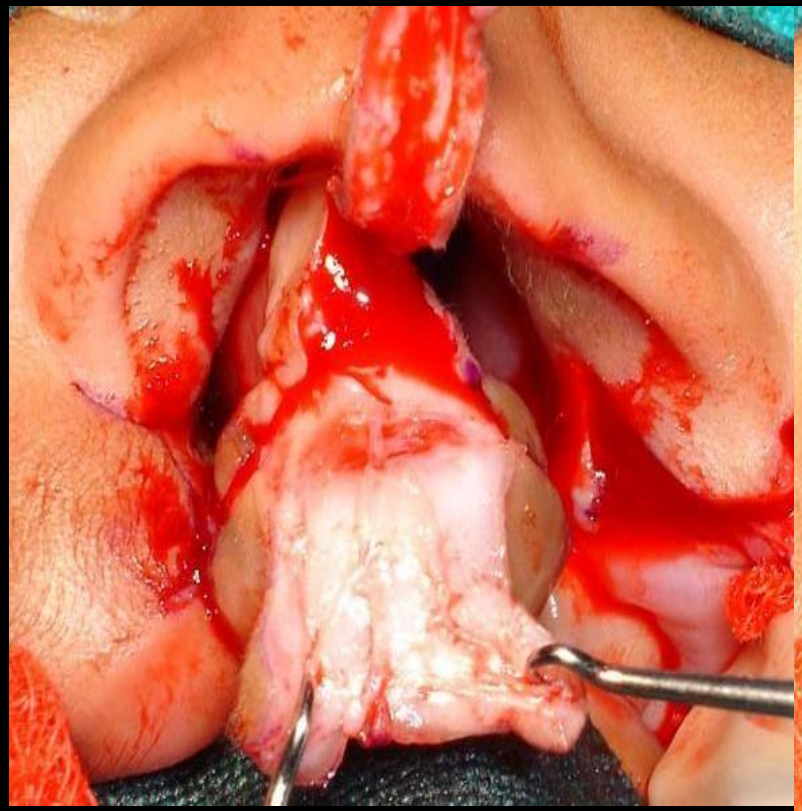

Dissection of the prolabium is done to separate vestibular mucosa from skin. All the fibro-adipose tissue is removed and the vestibular mucosa is trimmed

Bilateral Cleft Lip Repair

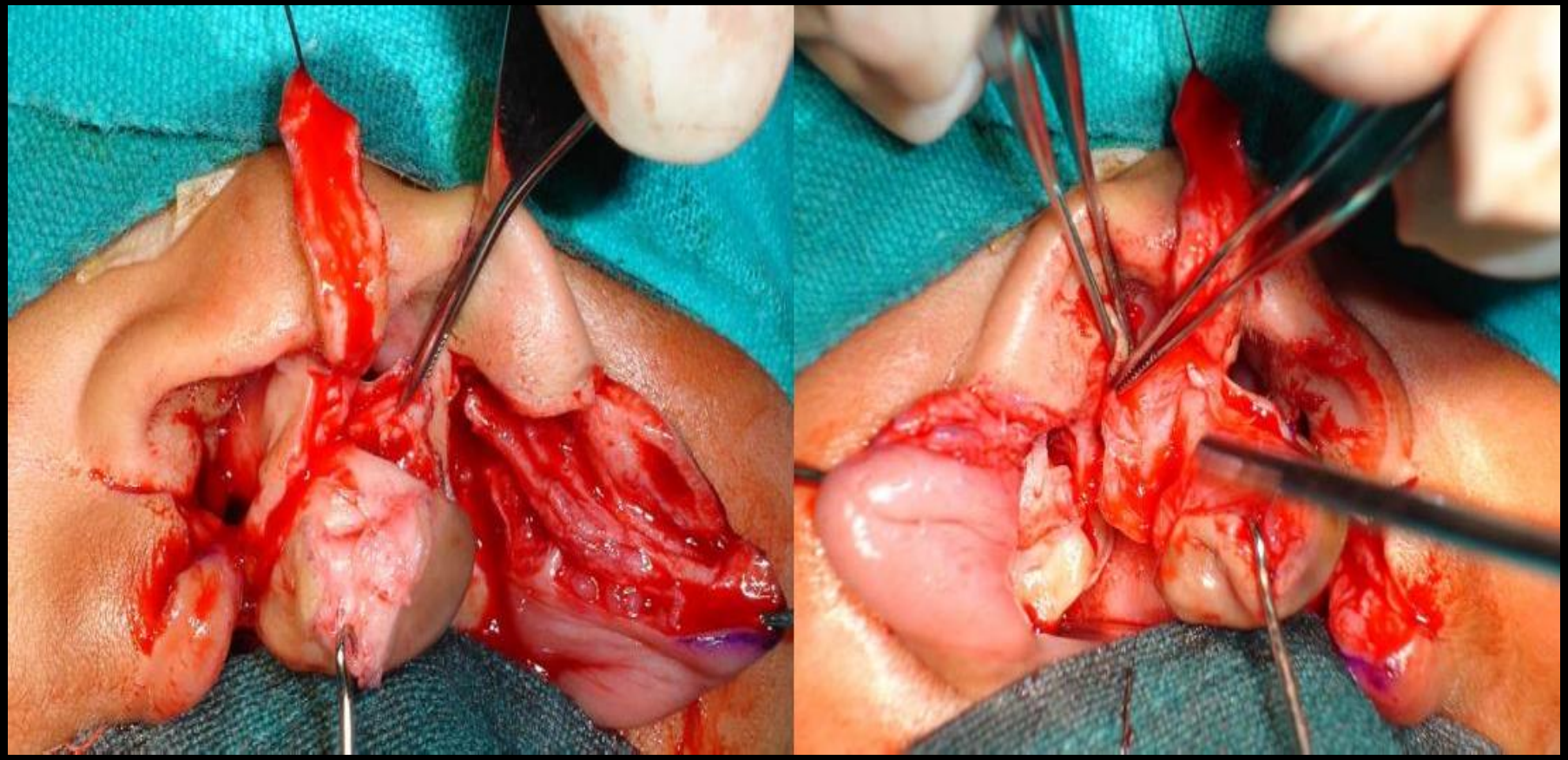

Periosteoplasty is done in patients who have associated cleft alveolus and/or cleft palate. It is done to receive the bone graft later on and to minimize the formation of “Y” junction fistula

Bilateral Cleft Lip Repair

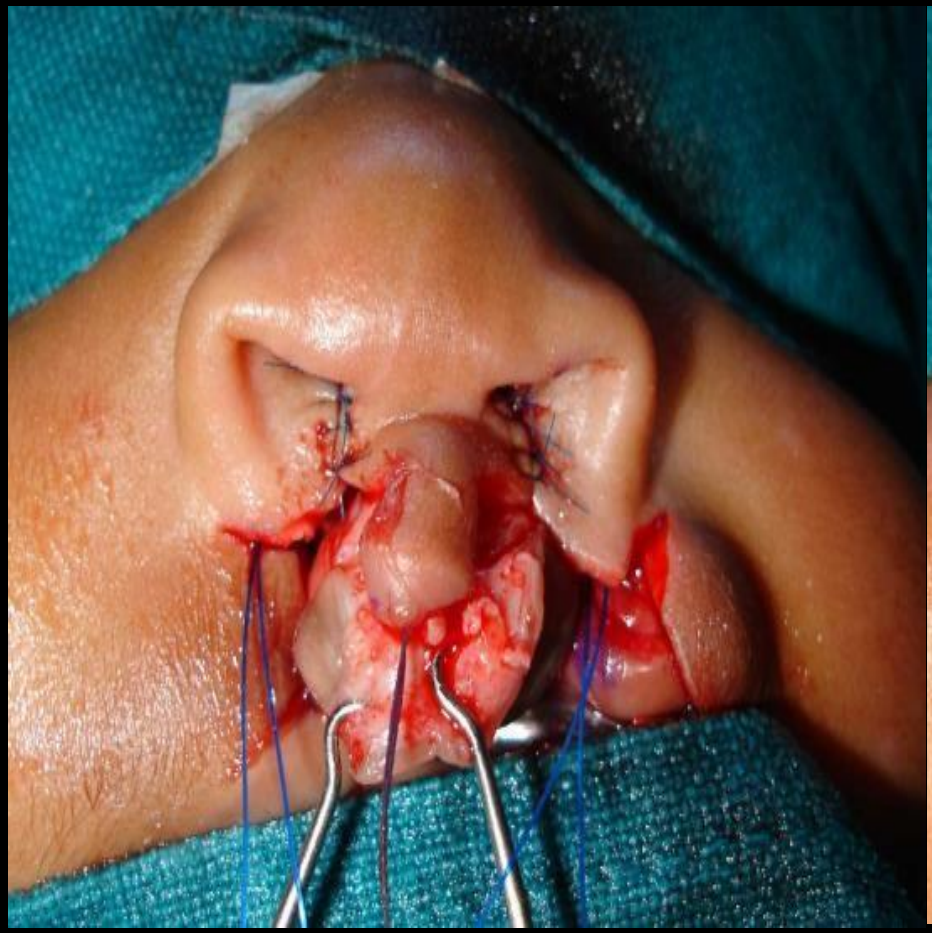

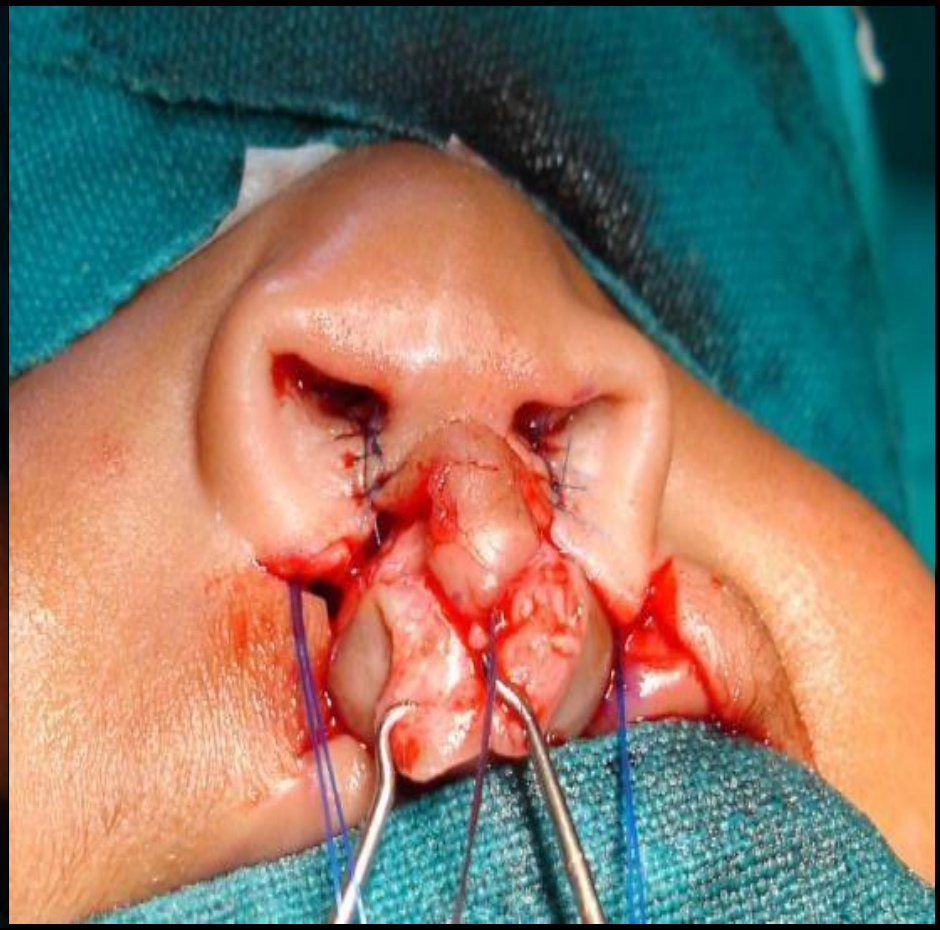

Nasal sill is closed bilaterally

Bilateral Cleft Lip Repair

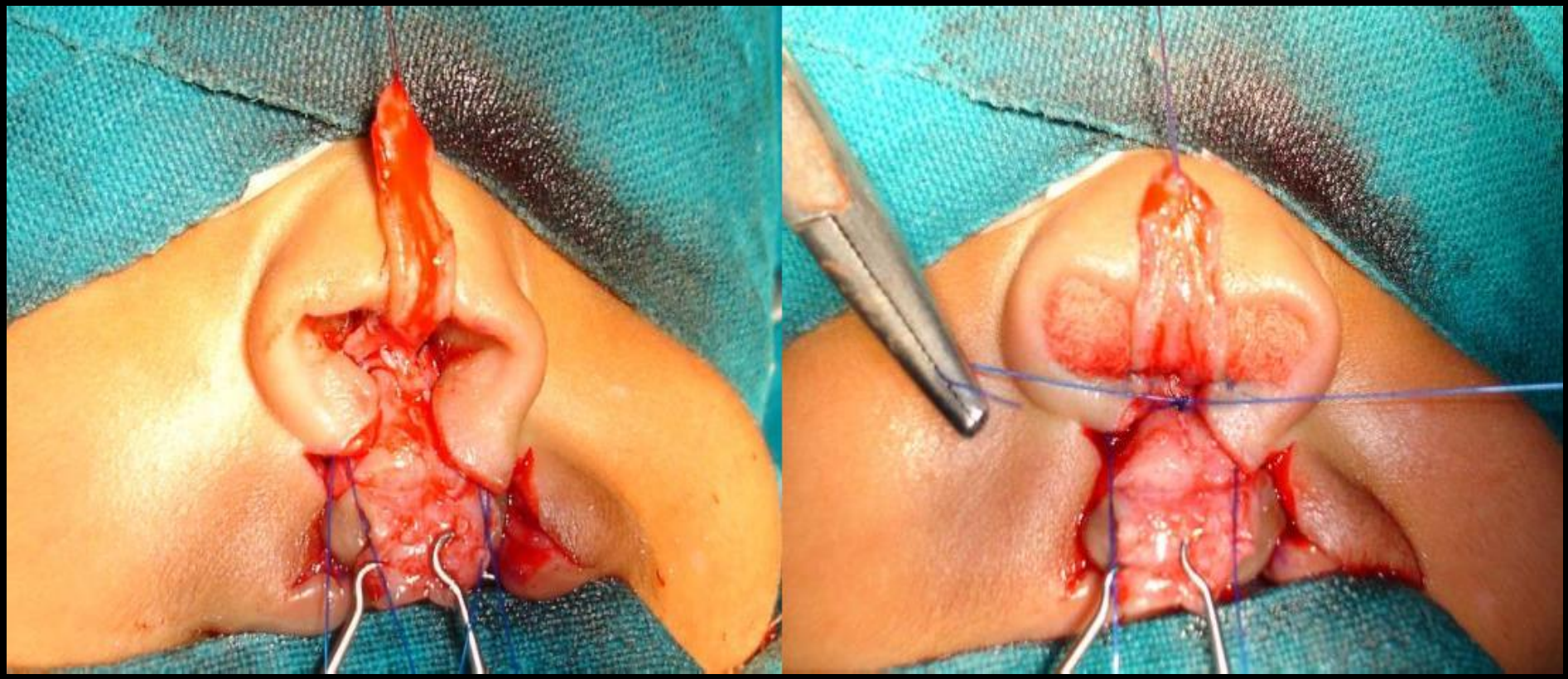

Ala of the nose is stabilized syymetrically.

Bilateral Cleft Lip Repair

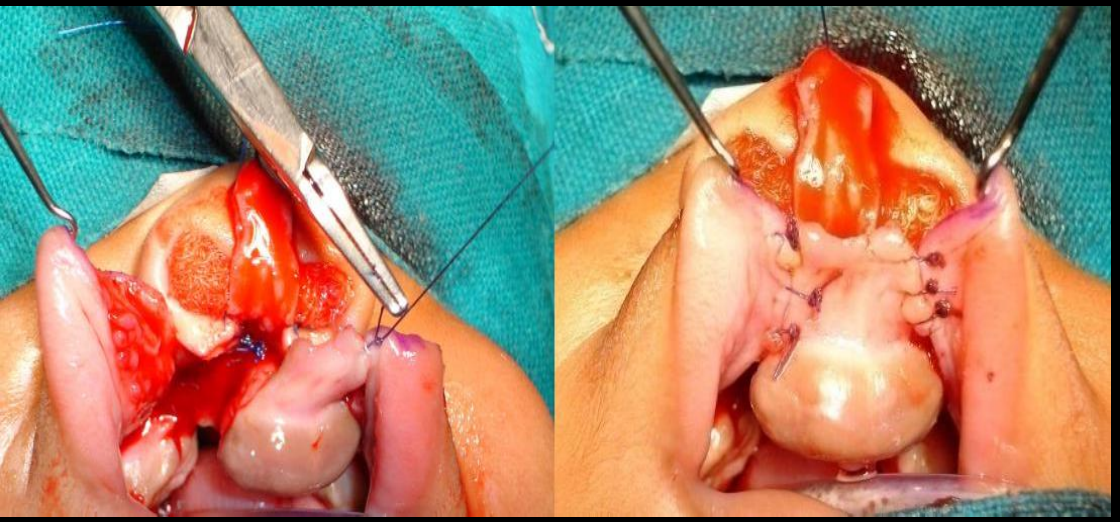

Vestibule formed with tissue from prolabium and corresponding labial mucosa

Tissue from prolabium is sutured to premaxilla

Vestibule formed by closing both side labial mucosa

Bilateral Cleft Lip Repair

Muscle approximation and closure is done

lww | 24/7/13 | 16:13 | 4 Color Fig(s): F2-3 | Art: PRS205695

A Comparative Study of Two Different Techniques for Complete Bilateral Cleft Lip Repair Using Two-Dimensional Photographic Analysis

Srinivas Gosla Reddy, M.B.B.S., M.D.S., Ph.D.
Rajgopal R. Reddy, M.B.B.S., B.D.S.
Max J. Zinser, M.D., D.D.S.
Likith V. Reddy, M.D., D.D.S.
Anthony F. Markus, F.D.S.R.C.S., F.D.S.R.C.P.S., F.R.C.S.
Stefaan J. Bergé, M.D., D.D.S., Ph.D.

Hyderabad, Hyderabad, India; Cologne, Germany; New Orleans, La.; Bournemouth, United Kingdom; and Nijmegen, The Netherlands

Background: The aim of this study was to compare the clinical outcomes of two techniques to repair complete bilateral cleft lip by using indirect two-dimensional photographic analysis.
Methods: One hundred eight bilateral cleft patients were included in this study, 54 patients operated on with the Millard technique and 54 patients operated on with the Afrose technique. Each group of patients was further separated into two subgroups containing symmetrical and asymmetrical cleft lips. All patients were photographed preoperatively and 4 years postoperatively in frontal and submentovertical views in a reproducible way. Eight measurements were performed on the photographs. From these measurements, seven ratios were calculated to compare the two techniques.
Results: The outcomes of the interobserver and intraobserver measurements were analyzed using the Pearson correlation test. There was a statistically significant reliability in the intraobserver and interobserver ratios. Analysis of the ratios was performed using the independent samples *t* test (5 percent level of significance). The authors found that the Afrose technique was better than the Millard technique in six of the seven parameters for symmetrical clefts and in four of the seven parameters for asymmetrical clefts; however, there was no statistically significant difference seen between the two techniques.
Conclusions: The Afrose technique seems to have good clinical outcomes on bilateral cleft lip patients, but more research and long-term follow-up are needed to determine the full outcome of the technique in various parameters. (*Plast. Reconstr. Surg.* 132: 00, 2013.)
CLINICAL QUESTION/LEVEL OF EVIDENCE: Therapeutic, III.

No greater problem exists in the whole field of surgery than the successful treatment of patients suffering from complete, bilateral cleft lip–cleft palate repair.[1] The challenge is to construct the nasolabial complex in three dimensions, incorporating soft and hard tissue and anticipating four-dimensional changes of growth and distortion.[2]

A number of surgical procedures with many variations for the repair of bilateral cleft lip are well described.[3–5] The Millard technique and its variations are extensively used to repair bilateral cleft lips.[6] The Afrose technique is based on a combination of a variation of the Millard technique on the cleft segment and a variation of the Pfeifer technique on the prolabium. The aim of this study was to compare the clinical outcomes of the Millard technique and the Afrose technique by using indirect photographic measurements in complete bilateral cleft lips.

From the G.S.R. Hospital, Institute of Cranio-Maxillofacial and Facial Plastic Surgery; the Department of Plastic Surgery, Clinic Cologne Merheim, University Witten-Herdecke; the Department of Oral and Maxillofacial Surgery, Louisiana State University Health Sciences Center, School of Dentistry; Nuffield Hospital; and Radboud University Nijmegen Medical Center.
Received for publication January 1, 2013; accepted March 22, 2013.
Copyright © 2013 by the American Society of Plastic Surgeons
DOI: 10.1097/PRS.0b013e31829ad195

Disclosure: *The authors have no financial interest to declare in relation to the content of this article.*

A comparative study of two different techniques for complete bilateral cleft lip repair using two-dimensional photographic analysis

Plastic and Reconstructive Surgery 2013

www.craniofacialinstitute.org

2 Dimensional Photographic Analysis

Results

SYMMETRICAL BILATERAL LIP

- Difference, statistically not significant (Afroze group better)

  Labial, nasal, and nostril symmetry

- Difference, statistically not significant (Millard group better)

  Vermillion symmetry

ASYMMETRICAL BILATERAL LIP

- Difference, statistically not significant (Afroze group better)

  Labial and nasal symmetry

- Difference, statistically not significant (Millard group better)

  Vermillion symmetry

Conclusion

The Afroze technique seems to have good clinical outcomes on bilateral cleft lip patients, although there were no statistical differences between the two techniques

Source:
Gosla Reddy S, et al A comparative study of two different techniques for complete bilateral cleft lip repair using two-dimensional photographic analysis. Plastic and Reconstructive Surgery, 2013

Long Term Follow-up of Bilateral Lip

Pre-Op

Immediate Post-Op

3 Months Follow-up

3 Years Follow-Up

6 Years Follow-Up

8 Years Follow-Up

15 Years Follow-Up

Pre-Op and 1 month Post-Op

Worm's Eye View – Pre-Op and 1 month Post-Op

Lateral View – Pre-Op and 1 month Post Op

4 Years Follow-Up

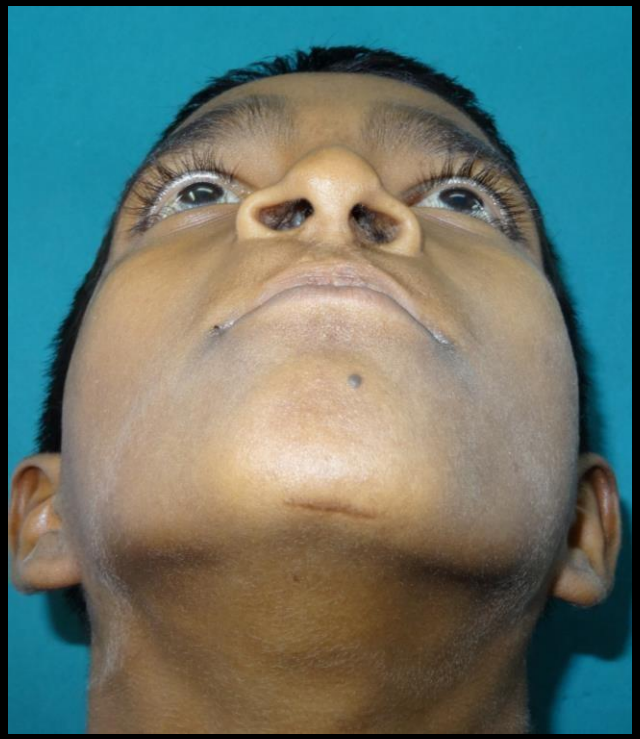

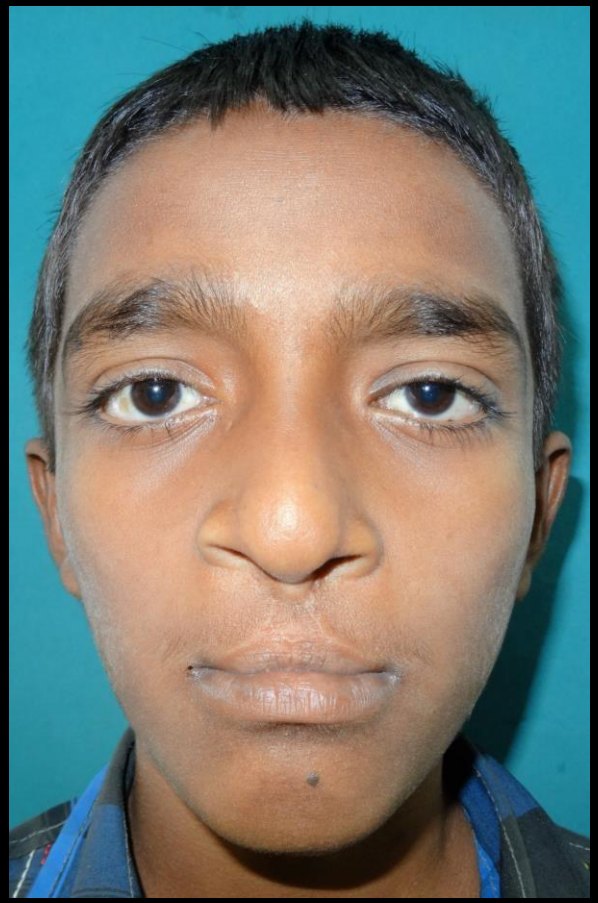

9 Years Post-Op

15 Years Follow-Up

Pre-Op

5 Days Post-Op

3 Years Follow-up

7 Years Follow-Up

15 Years Follow-Up

Pre-Op

One Year follow-up

One Year Follow-Up

6 Years Follow-Up

15 Years Follow-Up

Preoperative | 5 days postoperatively | 18 months postoperatively | 3 years postoperatively

Preoperative | 5 days postoperatively | 9 months postoperatively | 3 years postoperatively

Bring the Smile Back

Thank You

www.craniofacialinstitute.org